

# National Journal of Research in Ayurved Science

## Management of Acute Necrotizing Pancreatitis through Ayurveda

### Regimen: A Case Report

Soniya Gupta\*<sup>1</sup> Akash Kumar Gupta<sup>2</sup> R. K. Yadava<sup>3</sup>

1. P.G. Scholar 3<sup>rd</sup> Year of Department of Kaya Chikitsa
2. P.G. Scholar 2<sup>nd</sup> Year of Department of Shalya Tantra
3. Associate Professor & Head of Department of Kaya Chikitsa  
All India Institute Of Ayurveda, New Delhi

\*Corresponding author:  
drsoniyarac@gmail.com

#### How to Cite this article:

Management of Acute Necrotizing Pancreatitis through Ayurveda Regimen: A Case Report/ Soniya Gupta, Akash Kumar Gupta, R. K. Yadava/ Ayurlog: National Journal of Research In Ayurved Science 2019; 3(2): pages: 01-07

#### Ethical approval:

Approved by the Institutional ethics committee

#### Conflict of Interest:

None declared

Sources of Funding: None

#### Date of Submission:

24/01/2019.

#### Date of Peer Review:

12/02/2019.

#### Date of Acceptance:

20/03/2019.

#### Date of Publishing:

1/04/2019.

**Keywords** Acute Necrotizing pancreatitis, Acute Pancreatitis, Pitta dosha.

#### Name of Publication

Dudhamal Publications  
(OPC) Pvt. Ltd., Chembur,  
Mumbai, Maharashtra, India

**Abstract:** Necrotizing pancreatitis is an extreme complication of acute pancreatitis. Acute pancreatitis is an inflammation of the pancreas. Pancreas sits behind the stomach. One of its main functions is to make enzymes that help in digest the food. Normally, those enzymes flow through a small opening into small intestines. If pancreas becomes inflamed, the enzymes can start to leak into parts of the pancreas instead. These enzymes can sometimes kill pancreatic tissue, resulting in necrotizing pancreatitis. The dead tissue can get infected and cause life-threatening complications. Cardinal symptoms are abdominal pain (boring nature), nausea, vomiting, and tenderness in abdomen, pain worsened after eating, steatorrhea and weight loss. Assessments were made using Elevated levels of Serum Amylase and Lipase. In modern science, management is Lifelong enzymes, Periodical Emergency hospitalisation, IV fluids, painkillers, anti-inflammatory, and antibiotics, ERCP stunting, surgical intervention. It involves high cost, side effects and in many cases, there is progression of disease leading to fear, frustration and debility among sufferers. In Ayurveda three doshas are described as Vata, Pitta, Kapha. Pitta dosha we have substances exactly similar to enzymes. The features of acute pancreatitis are similar to the features of pitta where tikshna and ushna guna of pitta are aggravated. The observations reveal that, Ayurvedic regimen can play a key role in the management of conditions like pancreatitis. A 25 years old male patient diagnosed with acute necrotizing pancreatitis. At the end of the treatment, there was considerable improvement in the subjective and objective criterias. The treatment strategies followed in this study can be safely adopted under the supervision of competent specialist.

**Introduction:** <sup>1</sup>Pancreas is a digestive gland which performs a range of both endocrine and exocrine functions. In humans, it is located in the epigastrium and left hypochondrium. In adults, pancreas measures between 12 and 15 cm and is shaped as flattened tongue of tissue. The endocrine part produces several important hormones, including insulin, glucagon, somatostatin and pancreatic polypeptide which are involved in the homeostasis of blood glucose and are also involved in the control of upper GI motility and function whereas, the exocrine part is responsible for digestion of carbohydrates, proteins and lipids. The major enzymes involved in the digestion of proteins are trypsinogen and chymotrypsinogen. Those enzymes involved in the digestion of fats are lipase and amylase. Necrotizing pancreatitis occurs when acute pancreatitis is left untreated or isn't treated correctly. Most of the cases having pancreatitis from excessive alcohol consumption and gallstones. Pancreatitis may also result from injury to the pancreas, medication side effects, high cholesterol, and high calcium levels in the blood, autoimmune diseases, such as lupus, pancreatic tumor. In rare cases, necrotizing pancreatitis affects people with chronic pancreatitis. Chronic pancreatitis is a long-term condition,

whereas acute cases are temporary episodes of inflammation. Acute pancreatitis is a common disease with wide clinical variation and its incidence is increasing. The average mortality rate in severe acute pancreatitis approaches 2–10 %. <sup>2</sup>Pancreatic inflammatory disease may be classified as Acute Pancreatitis and Chronic Pancreatitis. Globally, the incidence of acute pancreatitis is <sup>3</sup>5 to 35/100,000 new cases per year worldwide, with a mortality rate of about 3%. The incidence of chronic pancreatitis is 8.2 new cases per 100,000 per year and a prevalence of 26.4 cases per 100,000. The formation of infected pancreatic necrosis or fluid collection occurs usually in the second week. Abdominal pain is one of the main symptoms of necrotizing pancreatitis. It can build slowly or come on quickly. Severe pain can be felt in front, near the stomach, and also wrap around the back. The pain may also become worse after eating, and the abdomen may become swollen. Other common symptoms include fever, nausea, vomiting, dehydration, rapid heart rate. <sup>4</sup>Respiratory failure is the most common type of organ failure in acute pancreatitis. In Ayurveda, *Pitta* has been described as *Agni* or fire, as it performs actions similar to fire such as <sup>5</sup>*pachana* (digestion), *dahana* (burning, combustion, oxidation), *parinamana*

(conversion), *paravritti* (transformation, mutation) *prakashana* (illumination, radiation), *ranjana* or *varnakaram* (coloration), *prabhakaram* (lustre) and *tapana* (heat production).<sup>6</sup> The physical qualities of *pitta* are *ishatsneha* (slightly viscous),

*Ushna* (hot), *tikshna* (sharp, penetrating or intense), *drava* (liquid), *amla* (when *vidagdha*, sour), *sara* (fluid) and *katu* (acid).<sup>7</sup> A type of *pitta*, *Pachaka pitta* may refer to the gastrointestinal hormones responsible for the excitation of *achhapitta* (which includes a wide variety of digestive secretions viz. bile, pancreatic juice and intestinal secretions).

Like *pitta* described in Ayurveda, the enzymes perform analogous functions viz. splitting or *sanghatabheda*, transforming or *parinamana*, mutation or *paravritti*; oxidation or *dahana*, etc. Like *pitta*, enzymes are also present, universally and are built up by the body from appropriate substances derived from *aharadravyas* (nutrition).<sup>8</sup> Thus, in *pitta* we have substances exactly similar to enzymes. The features of acute pancreatitis are similar to the features of *pitta* where *tikshna*

and *ushna guna* of *pitta* are aggravated. Such manifestations can be managed in Ayurveda successfully and a case has been treated that is presented here.

**Case report:** A 25 years old male patient with pain in abdomen and flatulence in the last 2 years attended the OPD, AIIA on 24.05.2018. Patient had history of addiction for excessive alcohol since seven to eight years. Initial history revealed that the patient developed pain in abdomen and referred to the back. Pain was severe and boring in nature. Patient also developed vomiting, one to two episodes. At that time patient was admitted in emergency ward of nearby allopathic hospital. He was diagnosed as a case of Acute Pancreatitis. Doctor suggested pain killer, antacids in injectable form and as above treatment exhausted, patient opted for *Ayurvedic* treatment and consulted in OPD No.-2, AIIA, NEWDELHI. On examination, patient was afebrile, conscious, well oriented, Pulse was 76/min, and blood pressure was 118/78 mm of Hg and on per abdominal examination there was tenderness in epigastrium and left hypogastrium region of abdomen.

#### **Criteria for selection of medicines:**

The present case was diagnosed as acute necrotizing pancreatitis in which *Pitta shamak* and *pitta rechana* medicines are preferred. Oral medication was selected on the basis of the properties of ingredients in the respective formulations that help in pacifying

aggravated *ushna* and *tikshna guna* of *Pitta dosha*.

**Assessment criteria:** Before and after treatment, assessment was made subjective and objective criterias using Serum Amylase, Serum Lipase level and NCCT Whole abdomen report.

**Table 1: Ayurvedic medicines adopted-** Considering the *pitta dosha* involvement these oral medicines were planned in this case.

DATE	MEDICINES	DOSE	SYMPTOMS OBSERVED
24/05/2018	1. <sup>9</sup> Swarna Sutashekhara Rasa	1 tab. Morning, (Before meal) with honey	Bowel was not clear, Heaviness in abdomen
	2. Punarnavamandoor	2 tab. BD	
	3. Arogyavardhanivati	1 tab. BD	
	4. Kamdudha Rasa	250 mg BD	
	Giloyasatwa	500 mg BD	
	<sup>10</sup> Avipattikar choorna	3 gm BD	
	5. <sup>11</sup> Phalatrikadi kwath	30 ml HS	

- Treatment was same continuing for 1 month from 24/05/2018 to 27/06/2018 but followed up after

15 days and vitals were monitored, mild relief in abdominal pain.

- Bowel was not clear throughout the treatment

**Table 2: Added medicine -**

DATE	MEDICINES	DOSE	SYMPTOMS OBSERVED
28/06/2018	Powder Bowelax	1 TSF HS	Bowel was clear and vitals were stable.

- Treatment was same continuing for 6 months from 28/06/2018 to

13/12/2018 but followed up after 15 days and vitals were monitored.

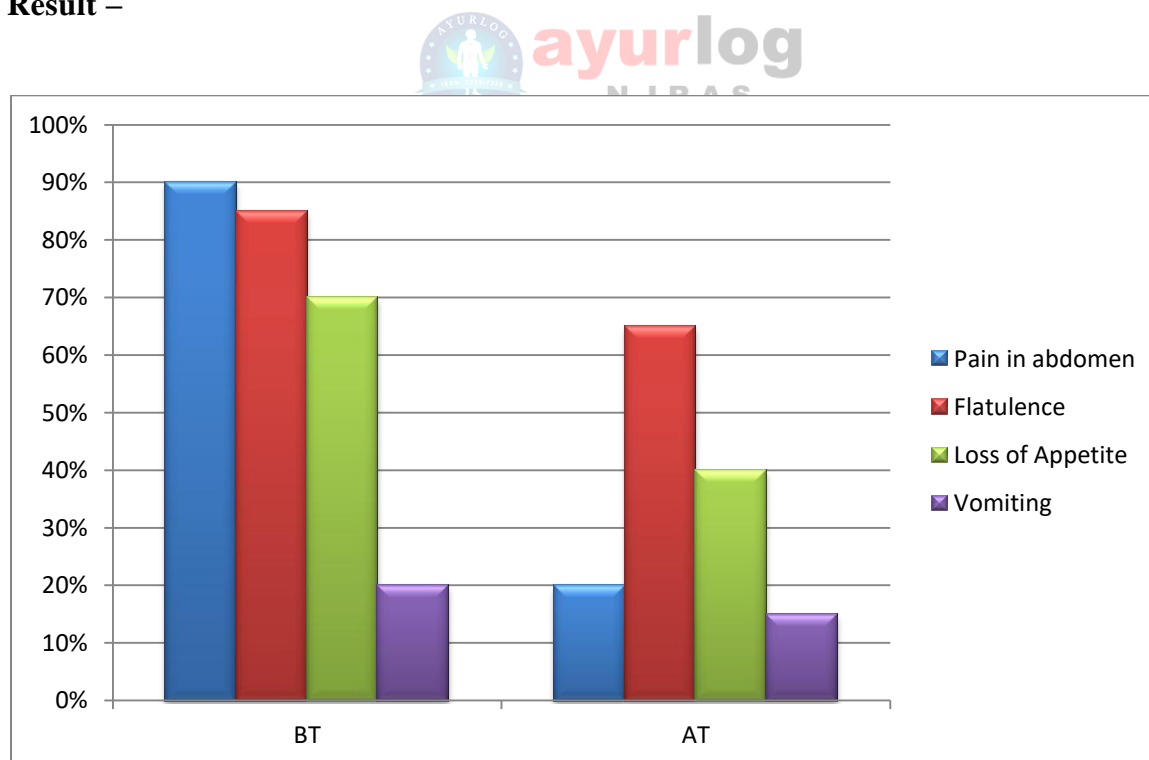
- On 09/08/2018, bowel was incomplete evacuation i.e. 2 to 3 times per day, appetite was decreased; B.P. was 120/76 mm of Hg and pulse was 74/min.
- But treatment was same continued.

- During the treatment, general condition was good and symptomatic relief and we suggested the laboratory investigations but not done by the patient.

**Observations:** After seven months of treatment –

DATE	Serum Lipase	Serum Amylase	NCCT Whole abdomen
15/05/2018	2,122 IU/L	977 U/L	Acute Necrotizing pancreatitis
07/12/2018	11.8 IU/L (Normal range = 0 to 60 IU/L)	41 U/L (Normal range = 0 to 100 U/L)	No significant abnormality detected in NCCT abdominal scan

**Result –**



It is observed that there was significant relief in the cardinal signs and symptoms of Acute Necrotizing Pancreatitis.

#### **Discussion:**

Pancreatic inflammatory disease may be classified as Acute Pancreatitis and

Chronic Pancreatitis. Any episode of acute pancreatitis is considered as an exacerbation of inflammation superimposed on Chronic Pancreatitis. It is evident that the endocrine part of pancreas produces several important hormones including insulin, glucagon, somatostatin and pancreatic polypeptides which are involved in the homeostasis of blood glucose and are involved in the control of upper GI motility and function whereas, the exocrine part is responsible for digestion of carbohydrates, proteins and lipids. The major enzymes involved in the digestion of proteins are trypsinogen and chymotrypsinogen. Those involved in the digestion of fats are lipase and amylase. Epigastric pain, nausea-vomiting and flatulence are the usual clinical features. In *Ayurvedic* view, the *dosha pitta* may be called as a by-product of *teja* and *Apa Mahabhuta*, means there is maximum presence of *tapa* (heat). This heat originated through the same gastrointestinal tract where pancreatic secretion is a component. It can be assumed that trypsin and chymotrypsin are the most heating and splitting substances which are liable of auto digestion means destruction of pancreatic cells itself. So, this evidence clearly shows a clear conclusion that pancreatic enzymes trypsin and

chymotrypsin are *tikshna*(sharp) and *ushna*(hot).



The features of acute pancreatitis are similar to the features of *pitta* where *tikshna* and *ushna guna* of *pitta* are aggravated. Necrotizing is due to *Pitta dosha* which is produced by the ill and inflamed pancreas.<sup>9</sup> *Swarna sutashekhara rasa* act as a *pitta shamak aushadhi* and as a *rasayan* also.<sup>11</sup> *Phalatrikadi Kwath* and *Arogyawardhani vati* have *Pitta rechaka* property.<sup>10</sup> *Avipattikar choorna* is also *pitta shamak*. Considering the *Dosha* involvement above oral medicines were planned in this case study.

### Conclusion:

This case study shows effectiveness of internal regimen in necrotizing pancreatitis. Whilst there is enormous scope for further research but still it proves that with proper diagnosis and proper treatment protocol. *Ayurveda* can be beneficial in such cases of acute necrotizing pancreatitis. Recovery in the present case was promising and worth documenting.

### References:

1. Samar Mitra. Anatomy. 5ed. Calcutta; Academic Publishers; 2000. 1.90p.
2. Dan L. Longo, Editor, Anthony S. Fauci, Editor, Dennis L. Kasper, Editor, Stephen L. Hauser, Editor, J. Larry Jameson, Editor, Joseph

- Loscalzo, Editor. Harrison's Principles of Internal Medicine 18ed. New Delhi. Mc GrawHil Medical; 2012. 2635p.
3. Dan L. Longo, Editor, Anthony S. Fauci, Editor, Dennis L. Kasper, Editor, Stephen L. Hauser, Editor, J. Larry Jameson, Editor, Joseph Loscalzo, Editor. Harrison's Principles of Internal Medicine. 18ed. New Delhi. Mc GrawHil Medical; 2012. 2629p.
  4. Beger HG, Rau BM. Severe acute pancreatitis: Clinical course and management. World J Gastroenterol. 2007; 13:5043. [PMC  free  article] [PubMed]
  5. C. Dwarkanath. Introduction to KayaChikitsa. 2ed. Varanasi. Chaukhamba Orientalia; 1986. 194p.
  6. C. Dwarkanath. Introduction to KayaChikitsa. 2ed. Varanasi. Chaukhamba Orientalia; 1986. 131p.
  7. C. Dwarkanath. Introduction to KayaChikitsa. 2ed. Varanasi. Chaukhamba Orientalia; 1986. 195p.
  8. C. Dwarkanath. Introduction to KayaChikitsa. 2ed. Varanasi. Chaukhamba Orientalia; 1986. 205p.
  9. Dr. Indra dev Tripathi and Dr. Daya Shankar Tripathi, Yogaratnakar, chapter - Amlapittapraaran, page no. 670.
  10. Prof. Siddhinadan Mishra, Kaviraj Govind das sen, Sidhhiprada, Bhaishajyaratnawali, volume-2, chaukhambhaprakashana, chapter- 56/24-28, page no. 903
  11. Dradhabala and Charaka, Agnivesa, Charak Samhita, Chaukhambha Bharati academy, part-2, chikitsasthana, chapter- 6/40, page no. 240

---

End of article